

## EFFECT OF LOCAL FACTORS

As noted adjacent, peri-implantitis is multifactorial in etiology, however, there are factors that increase the risk of peri-implantitis that are within our control. Occlusal overload, bulky restorations or cement extrusion can be prevented by the dentist and can play a significant role in the destruction of bone in the susceptible patient. And because the ill effects are so grossly detrimental around an implant as opposed to a tooth (see below), and because we do not always know whose tissues will 'over-react' to a tiny open margin or a bit of cement, we must treat every patient with universal precautions for risk of peri-implantitis.

- Adjust occlusion so that there is equal distribution of load on all teeth.
- Fabricate an occlusal guard in patients with significant wear.
- Use TempBond that is radio-opaque and easy to remove.
- Don't over fill the crown with cement or the screw access to the top.
- Fill screw access half way with inorganic filling (Teflon tape, Cavit) to prevent colonization by bacteria.
- Place retraction cord prior to cementation to help remove any subgingival cement.

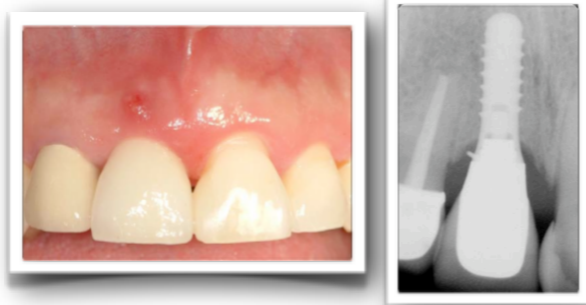We must also realize that if the patient can't access their tissues for hygiene because of a bulky crown, this must also be addressed though:

- Proper implant depth to allow for ideal emergence profile of the abutment.
- Use of a custom abutment to create a natural emergence profile and bring cement margins more coronally.

## WHAT IS PERI-IMPLANTITIS?

Peri-implantitis is defined as infection and inflammation around an implant that results in loss of supporting bone around the implant. It is similar to periodontitis, but affecting an implant rather than the supporting structures of the tooth. Peri-implant mucositis is the initial stage of inflammation where no bone has been lost (equivalent to gingivitis around teeth). Peri-implantitis should not be confused with the normal bone remodeling around an implant that can occur within the first several months after an implant is restored.

Peri-implantitis has a prevalence of 10% after 5-10 years of implant placement (COIR 2012). Causes include smoking, uncontrolled diabetes, occlusal overload, poor oral hygiene, genetic susceptibility to and history of periodontitis, and local factors such as bulky restorations and cement extrusion. It can present as diffuse erythema and inflammation around the entire keratinized mucosa of the implant, or as a localized fistula as shown in the photograph below, due to cement extrusion as visualized in the radiograph.



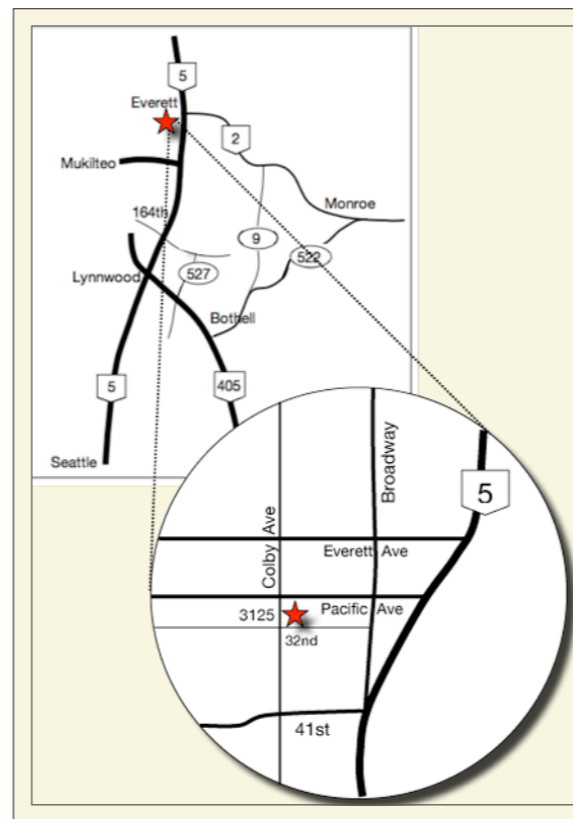
Courtesy: Dr. Darrin Rapoport

Please enjoy this issue of **ProbeTips** which will review the current treatment options for resolving peri-implantitis, and our best tools for prevention.

Copyright 2013 Dr. Pamela Nicoara

Pamela A Nicoara DDS MSD PLLC

PERIODONTOLOGY IMPLANTOLOGY ORAL MEDICINE



3125 Colby Avenue, Suite H  
Everett WA 98201

T: 425-374-5380 F: 425-374-5382

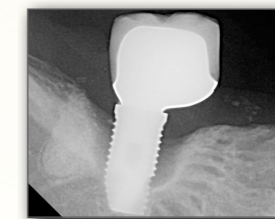
www.NICOARAPERIO.com  
doctor@NICOARAPERIO.com

# PROBE TIPS

A QUARTERLY PERIODONTAL  
NEWSLETTER

BY PAMELA NICOARA DDS MSD

## Peri-Implantitis Treatment and Prevention



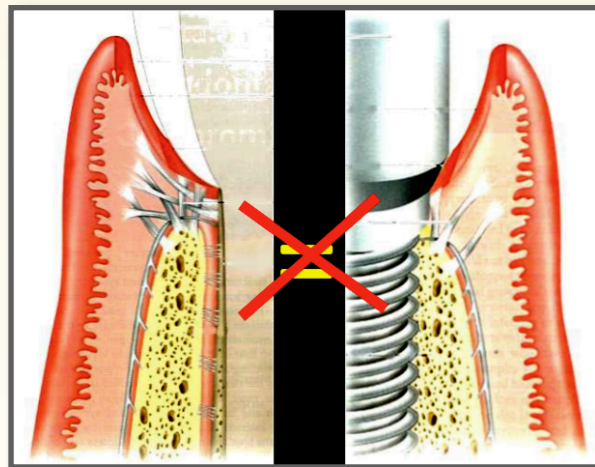
VOLUME 6, NO. 2

AUGUST 2013

# Treatment and Prevention of Peri-Implantitis

## GENERAL CONSIDERATIONS

It is important to recognize that soft tissue around a tooth is not the same as the soft tissue around an implant. Around a tooth, there is a firm connection of gingival fibers at right angles into the cementum (Sharpey's Fibers) with approximately a 1-3mm sulcus depth before this connective tissue attachment begins. The connection of the gingiva to the implant surface is weaker and is made through hemi-desmosomal attachment. The sulcus depth is also generally much deeper, particularly interproximally, and reaches an average of 5-6mm rather than 3mm.



In addition, the way we restore teeth is different to the way we restore implants. Crown margins around teeth are usually only 1mm subgingival. However, particularly if stock prosthetic abutments are used, the crown margin may lie 3-6mm subgingivally (especially interproximally).

## NON-SURGICAL TREATMENT

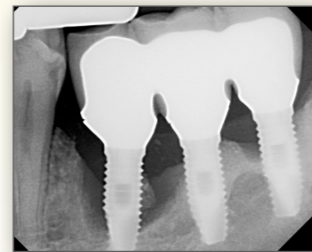
Non-surgical treatment of peri-implantitis is similar to the treatment of periodontitis and is aimed at removing plaque and subgingival calculus

accumulations. It can be divided into professional treatment and self-treatment.

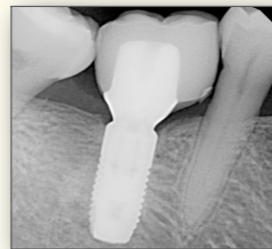
Professional treatment includes the use of curettes made of plastic or titanium, ultrasonic instruments with plastic tips, and lasers. Systemic and local antibiotics can also be used. Unlike teeth, the use of air-abrasion is also a possibility if access is available.

On the part of the patient, hygiene is critical. The use of subgingival irrigation with a WaterPik is beneficial, along with good brushing techniques either with a manual or sonic toothbrush, all of which should be used after initial therapy is complete.

As mentioned above, the shape of the restoration is very influential. Lack of access due to supra-structure may limit the efficacy of non-surgical debridement, particularly when crowns are splinted, and removal of the restoration may be



Splinted Crowns



Bulky Restoration considered (and possibly replaced with a better fitting restoration).

Peri-implant mucositis can successfully be reversed, but peri-implantitis is much more difficult to control once bone is lost and the implant surface is contaminated with bacteria.

## SURGICAL TREATMENT

Multiple techniques are available for surgical treatment of peri-implantitis and fall into three categories: Flap access, Resection, and Regeneration.

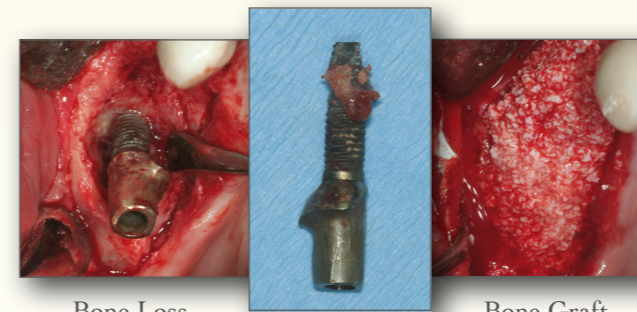
Surgical flap therapy allows access to underlying implant surfaces where it may be beneficial to remove

exposed threads and smoothen the implant surface.

Sharp ledges of bone which would impede hygiene, or maintain a deep pocket and cannot be grafted, should be removed.

Regeneration in the form of bone grafting can be performed with or without the use of a membrane. Success of bone grafting, similar to bone grafting around teeth, is dependent on having more bony walls available to graft against.

Unlike teeth, however, the overwhelming inability to decontaminate the implant surface, despite the use of lasers, air abrasion, removal of implant threads, use of various chemicals like citric acid, chlorhexidine, iodine, hydrogen peroxide and multiple different local and systemic antibiotics, means that successful treatment of peri-implantitis is rare.



Bone Loss

Bone Graft

## IF AN IMPLANT IS LOST OR NEEDS TO BE REMOVED...

The most current literature review by the Cochrane Collaboration indicates that there is no one method of non-surgical or surgical treatment of peri-implantitis that is proven to be more effective over another. In fact, the harsh reality is that once an implant is infected, it is not likely to resolve as follow up longer than 1 year indicated up to 100% recurrence of disease.

In the case when chronic infection will just continue to cause bone loss, and multiple treatments have failed

to resolve the infection, then removal is necessary. This can be quite a destructive process when some areas of the implant remain integrated (see adjacent panel). The consequence is significant bone loss which may require multiple surgeries to attempt to regain what was lost, if it is even possible to regain it. Palatal, lingual or interproximal bone is the most precious in that regard, and is nearly impossible to replace in many cases.

## THE CRITICAL ROLE OF IMPLANT MAINTENANCE

When implant infection can be so costly and destructive, preventing infection is a high priority. As mentioned before, patient home care is extremely important. Access and the use of a WaterPik in particular are most beneficial. Research indicates that oral antibacterial mouth rinses, such as Listerine, when combined with good home care, are also useful.

Regular professional maintenance is advised as well. Professionally, implants should be cleaned with instruments softer than the implant surface to prevent roughening of the implant surface which would increase areas for bacterial colonization. As mentioned before, there is no proven most effective method for cleaning around an implant, so its not as important what you use to clean and navigate around the hardware that is a titanium tooth replacement, as long as you are effective and not causing more damage.

## REFERENCES

- Cochrane Database* Esosito et al. 2012.
- Cochrane Database* Grusovin et al. 2010.
- J Can Dent Assoc.* Todescan et al. 2012.
- COIR.* Klinge et al. 2012.
- J Evid Based Dent Pract.* Romanos et al. 2012.