

PRINCIPLES OF ESTHETIC IMPLANT RESTORATIONS

☞ Restoring implants so that they look like natural teeth can sometimes be a challenge. There are certain biological and physical limitations which can keep things from looking their best. This issue of ProbeTips is intended to provide a few basic guidelines so that you can give your patients the correct expectations when it comes to replacing missing teeth with implants.

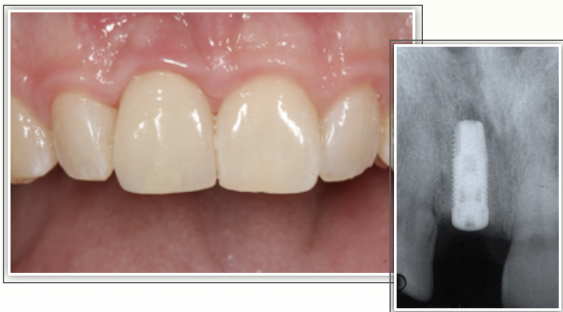The contours of the restoration itself are critical, but there are a few principles regarding the implant position and available soft and hard tissue which can dictate the way things go. First, there is a big difference between replacing a single missing tooth with adjacent teeth present, versus replacing several missing teeth, be it anterior or posterior. We'll address missing a single anterior tooth first as this is commonly the most challenging area to restore.

SINGLE ANTERIOR TOOTH

Of all the things that can tip you off to an un-natural restoration, the lack of a papilla is the most obvious.

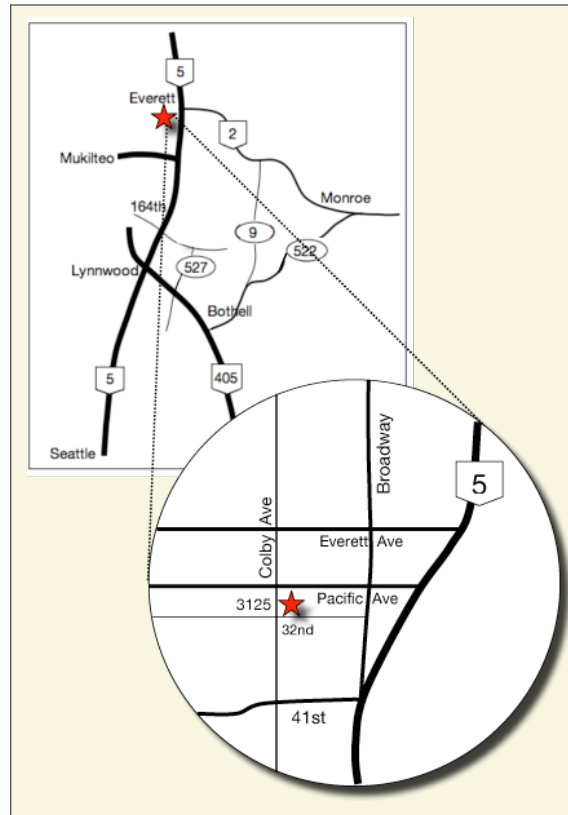
1. If there are papilla present at initial presentation, you should have papilla present after implant placement.
2. On the flip side, if there are no papilla present initially, without the use of orthodontics, it is nearly impossible to create a papilla. The papilla is present based on underlying bone. Only orthodontics can predictably put bone back where it was missing, at the price of restoring the extruded tooth with coronal prosthetics and/or endodontic treatment.

cont'd ...



Pamela A Nicoara DDS MSD PLLC

PERIODONTOLOGY IMPLANTOLOGY ORAL MEDICINE

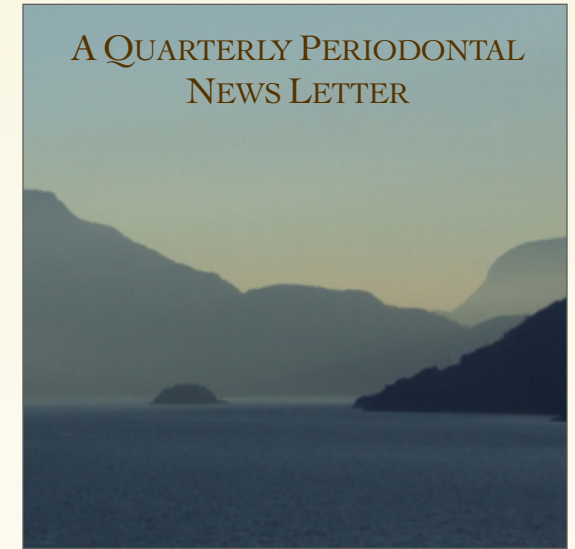


3125 Colby Avenue, Suite H
Everett WA 98201
T: 425-374-5380 F: 425-374-5382

www.NICOARAPERIO.com
doctor@NICOARAPERIO.com

PROBE TIPS

A QUARTERLY PERIODONTAL
NEWS LETTER



Esthetic Implant Restoration

VOLUME 1, No. 3

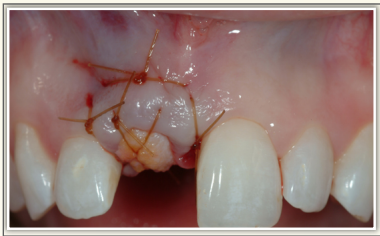
NOVEMBER 2008

Esthetic Implant Restoration

Cont'd from prior page...

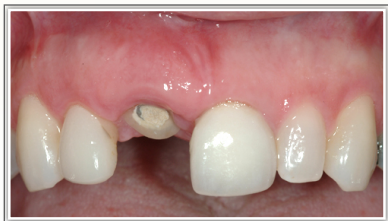Besides the papilla, the soft tissue in general is very important to the overall look of the restoration. It can often hide a lack of bone and create root prominence when it is lacking.

1. Facial recession can generally be addressed with connective tissue grafting at the time of implant placement without the use of orthodontics provided that the remaining root is not so large that the implant cannot gain primary stability in the remaining bone.
2. Nearly all anterior implant cases are treatment planned to receive a connective tissue graft to provide the most esthetic outcome possible.



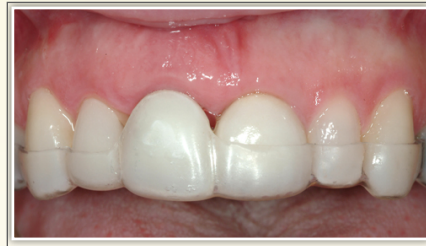Maintaining as much bone and soft tissue as possible from the start is of paramount importance.

1. Immediate implant placement on the day of extraction meets these objectives and allows the surgeon to maximize the use of the remaining bone and graft bone into socket space to keep as much tissue from resorbing as possible and to provide the most esthetic long term outcome possible.
2. Depending on the amount of soft tissue grafting necessary and the stability of the implant, a custom healing abutment can also be used to maintain tissue proportions.



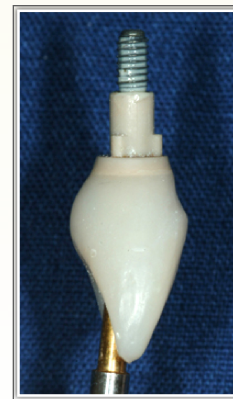A healing period is required in which the implant, if not already submerged, should remain undisturbed.

1. Typically, an Essix appliance is used for the first few weeks of healing which can be cut back to allow for swelling.
2. A more esthetic 'flipper' is fabricated for the remainder of the healing phase.



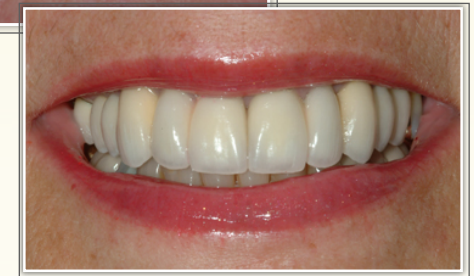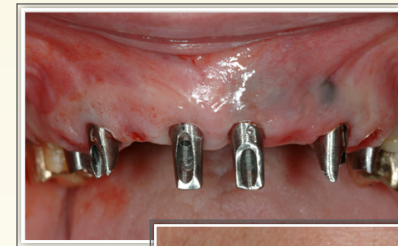Sculpting the tissues with a temporary implant crown is critical to determining the contours of the final restoration. Several weeks may pass as the temporary is adjusted to allow the tissues to adapt to the new crown and reach a final esthetic endpoint.

1. A smooth emergence profile should gradually extend from the subgingival implant platform to the supragingival interproximal contact.
2. Adequate embrasure space should be present to allow the papilla to fill in.
3. Creating a CEJ in the composite will help to provide a place for the facial soft tissue to predictably form.
4. Duplicating these subgingival contours in impression material will ensure that the lab will create a final crown which matches what you've worked so hard to develop.



MULTIPLE MISSING TEETH

The biggest difference with multiple missing teeth is the difficulty or inability to maintain a papilla between the implants or pontics of an implant supported fixed partial denture. If enough teeth are missing, all the papilla are shortened and it is easy to mask the lack of papilla as shown in the photographs below. Complete maxillary or mandibular implant supported dentures will be discussed in another issue of ProbeTips.



SUMMARY

Make sure your patients understand that oftentimes single missing or broken teeth can be immediately replaced with an implant, but not without soft tissue grafting as a minimum. At least 3 months of healing is required, and the temporary tooth replacement will take several forms until the desired result is ready to be duplicated in the final crown.

For multiple missing teeth, optimal esthetics will be hard to achieve with regard to papilla preservation, but can often be masked with the final restoration. ✍